

# BREAST IMPLANTS, ADVERSE EVENTS AND RARE COMPLICATIONS: FINDINGS BY MAMMOGRAPHY, US AND MR IMAGING

Implantes mamarios, eventos adversos y complicaciones poco frecuentes: Hallazgos por mamografía, ecografía y resonancia magnética

Flor Marina Medina Ch.<sup>1</sup>  
 José Abella Calle<sup>1</sup>  
 Óscar Eduardo García Ledesma<sup>1</sup>  
 Jessica Carolina Echeverry<sup>2</sup>



## Key words (MeSH)

Breast implants  
 Implant capsular contracture  
 Seroma  
 Adjuvants, immunologic

## Palabras clave (DeCS)

Implantes de mama  
 Contractura capsular en implantes  
 Seroma  
 Adyuvantes inmunológicos

## Summary

**Introduction:** At present, breast augmentation with implants is an increasingly common procedure, be it solely for cosmetic reasons or for reconstructive purposes after mastectomy. There are widely known local complications associated with this intervention, such as implant rupture and encapsulation, but there are other less common complications too, such as anaplastic lymphoma and autoimmune/inflammatory syndrome induced by adjuvants (ASIA). **Objective:** To review the imaging characteristics of frequent and infrequent complications associated with breast augmentation with implants. **Methodology:** Cases of different complications were retrospectively collected, in order to review mammography, ultrasound, CT and MRI images of patients with such complications at the Fundación Valle del Lili Clinic (Cali, Colombia) over the past two years. **Conclusions:** It is common to find post-surgical changes due to breast augmentation with implants. The study concludes that although mammography has a limited role in the assessment of implant complications, it remains the main screening tool for cancer in augmented breasts. Ultrasound is a very useful and cost-effective tool in evaluating implants. MRI with silicone sequences has the highest sensitivity and specificity when assessing the integrity of the implant and breast tissue as a whole.

## Resumen

**Introducción:** En la actualidad, la mamoplastia de aumento con implantes es un procedimiento cada vez más común, con fines exclusivamente cosméticos o reconstructivos después de una mastectomía. Existen complicaciones locales ampliamente conocidas, como la ruptura y contracturas capsulares, pero también se le han atribuido otras complicaciones menos frecuentes, como el linfoma anaplásico y el síndrome autoinmune/inflamatorio inducido por adyuvantes (ASIA). **Objetivo:** Revisar las características por imagen de las complicaciones frecuentes e infrecuentes asociadas al aumento mamario con prótesis. **Metodología:** Recolección retrospectiva de casos con complicaciones relacionadas con implantes mamarios; revisión y edición de las diferentes modalidades de imágenes en pacientes de la clínica Fundación Valle del Lili de Cali durante los dos últimos años. **Resultados:** Es frecuente encontrar cambios postquirúrgicos por mamoplastia de aumento con implantes. Aunque la mamografía tiene un papel limitado en la valoración de las complicaciones del implante, continúa siendo la herramienta de tamizaje de cáncer en la mama aumentada. La ecografía es un instrumento muy útil y costo-efectivo en la evaluación de los implantes. La RM con secuencias de silicona es la modalidad con más alta sensibilidad y especificidad si se quiere valorar la integridad del implante y el tejido mamario en su conjunto.



<sup>1</sup>Radiologists, Department of Diagnostic Images, Fundación Valle del Lili. Cali, Colombia.

<sup>2</sup>Four year resident. Department of Diagnostic Images, Fundación Valle del Lili. Cali, Colombia. Universidad CES. Medellín, Colombia.

## Introduction

Breast augmentation is one of the most popular cosmetic procedures among women and, while it is true, there are no trustworthy figures in our country, the International Society of Aesthetic Plastic Surgery (ISAPS) states that Colombia occupies the sixth spot in the world in performing this surgical procedure (1).

Breast images contribute to the diagnosis of complications associated to the implants, taking into account that clinical and physical exploration has limitations (2-4). The radiologist must be familiarized with the most usual and unusual findings of implants; additionally, he/she must know which are the advantages and limitations of each diagnostic method to detect an abnormality (2,5).

A search of representative cases of adverse events and low frequency complications associated to breast implants was made. Complications derived from silicone gel implants can be classified in locals, being these early or late, and in systemics (figure 1) (6).

## Technical considerations

Just like in patients without breast implants, the function of a mammography is the early detection of cancer (7-9).

The single technical factor that most affects the mammography is the density of the implant. The best projection is the augmented breast is obtained with the displacement technique of Eklund; with this technique the visualization area is enlarged up to 5% and allows a larger compression of the breast tissue and decrease of superimposed densities (7, 10). The position of the implant also interferes with the visualization; in the case of the sub-glandulars there is a 37% reduction of the visualized area, while in the sub-muscular it is of a 17% (7).

The ultrasound is of low cost and widely available. It must be performed with a linear transducer of at least 12 MHz to obtain images of the 12 axes of the breast, with special attention to the edge of the implant and the foldings. Besides, tools such as expanded field of vision must be used that allow to evaluate the totality of the implant. The limitations of the method include the evaluation of the posterior wall of the implant, the detection of residual silicone granulomas or previous silicone injections, which produce attenuation of the ultrasound beam (11). The magnetic resonance (MR) has a high spatial resolution that allow an adequate characterization of the implant and of soft tissues (2). It must be done with a 1.5 T or 3 T machine, and with breast antenna to ensure the quality of the image (12). The specific sequences with T2 information and fat saturation Fat Sat (T2-FS) with silicone and water suppression are essential. For the evaluation of the integrity of the implants contrast medium is not required; however, this is indispensable if characterization of the inflammatory or parenchymal tumour lesions is required (2,12).

## Local complications

### *Post-surgical collections*

The peri-implant collections are secondary to the surgical procedure or for reaction to a foreign object (13-15). They can correspond to seromas, hematomas or infection. In ultrasound, the collection can be anechoic, with multiple echoes, liquid-liquid levels, or present septi.

In MR it is possible to characterize the collections and its relation with the peri-prosthetic capsule, given that they present high signal intensity in sequences susceptible to liquid and persist like this in sequences with silicon suppression.

The infection rate posterior to implant is below 2.5% and two thirds of these occur in the acute post-surgical period (16-17). Just in symptomatic cases in which the collection persists or there is suspicion of infection is it indicated to take an image, ideally ultrasound, followed by percutaneous drainage (figure 2).

### *Capsular contracture*

Consists in the hardening and deformity of the fibrous capsule that leads to clinical deformation of the breast (14,18,19). It is the most common complication of implants, with rates varying from below 10% to more than 60% (20-22). Its exact cause is unknown, though there are associated factors such as the use of silicone implants and the sub-glandular localization (13,14,18,23).

Since it is a clinical diagnosis, radiologic findings are not always identified (24). In mammography, the implant looks rather spherical than oval, with irregular contours and focal bulges (13,14). Ultrasound (US) and MRI findings are less apparent: areas of capsular thickening, and increase in folds and in the anteroposterior diameter can be observed (figure 3) (14,15,25).

### *Prosthesis rupture*

It is the most common cause of implant retrieval (15,17,26,27). Its incidence is unknown and has been associated with the type of implant. According to the available specialized literature, historically there have been five generations of breast implants developed; the last generations have a cohesive silicone gel (consistency more like that of a flexible solid than to a liquid). This characteristic prevents the complete collapse of the implant, decreases the probability of leaks and migration of the implant's content, as opposed to the first generations (liquid silicone). The last breast implant generations can have a smooth or texturized cover, with the last one associated to a lower possibility of capsular contraction (28).

In patients with fifth generation implants which have cohesive gel and texturized cover, the informed rupture rates are of 10-14% in 8-10 years (28, 29); however, this rate increases in the cases of reconstructive surgery after oncological treatment. The last generation implants contain thick silicone more similar to a flexible solid than to a liquid. This increase in density confers the implant with a more firm consistency with lower contracture frequency, and, in the case of rupture, allows for the silicone to stay united in a uniform way, conserving its form.

When normal saline solution (NSS) implants break, these collapse and the body absorbs it in a few days (14,25). The physical exam or mammography is enough to confirm breakage (25). If the capsule is densely calcified the collapse can be partial or not present at all (figure 4) (14).

The ruptures of silicone implants are classified, according to the localization of the silicone with respect to the fibrous capsule, in intracapsular and extracapsular (figure 5).

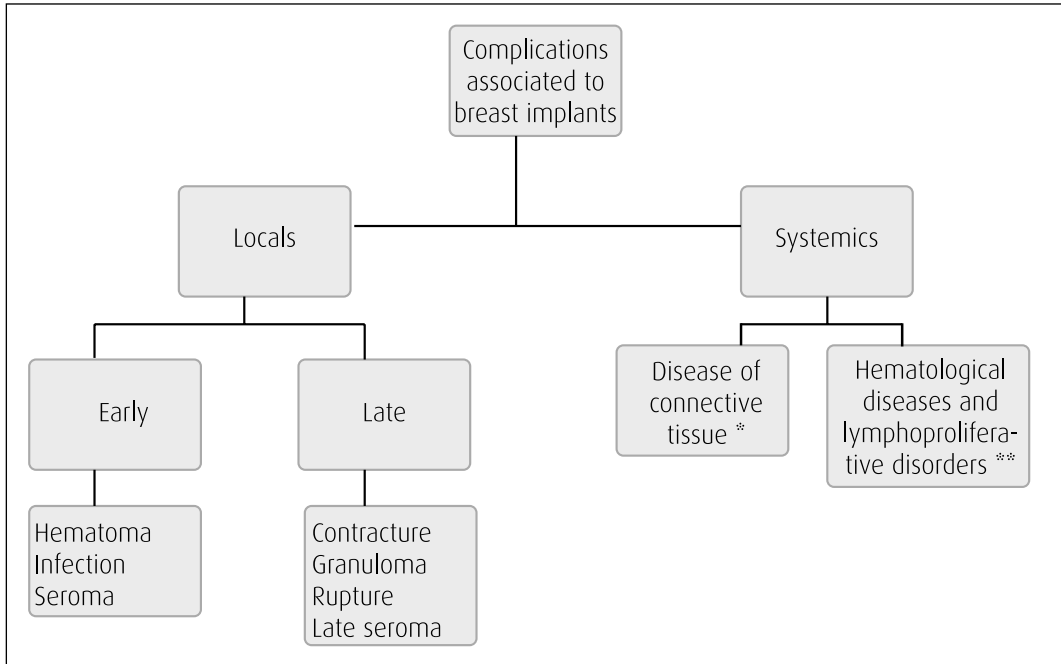


Figure 1. Classification of breast implant complications

\* Autoimmune / inflammatory syndrome induced by adjuvants.  
\*\* Giant cell anaplastic lymphoma.

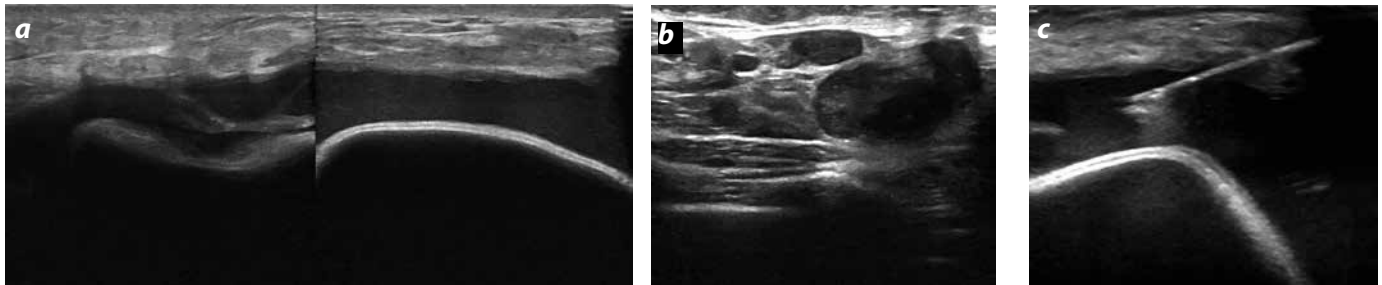


Figure 2. Post-surgical collection ultrasound in right breast. a) Shows a peri-implant collection with low-level echoes. b) Right axillary lymphadenopathies. c) Percutaneous drainage guided by ultrasound. Cultures showed infection by *Mycobacterium Abscessus*.

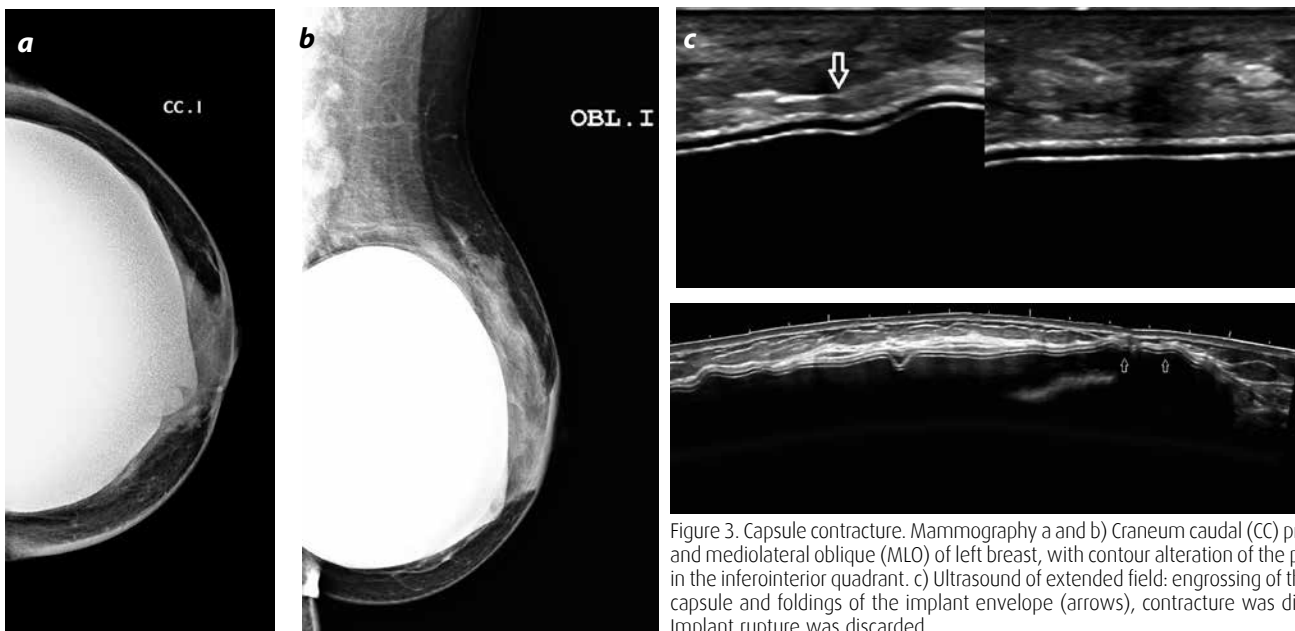

Figure 3. Capsule contracture. Mammography a and b) Craneum caudal (CC) projections and mediolateral oblique (MLO) of left breast, with contour alteration of the prosthesis in the inferointerior quadrant. c) Ultrasound of extended field: engrossing of the fibrous capsule and foldings of the implant envelope (arrows), contracture was diagnosed. Implant rupture was discarded.

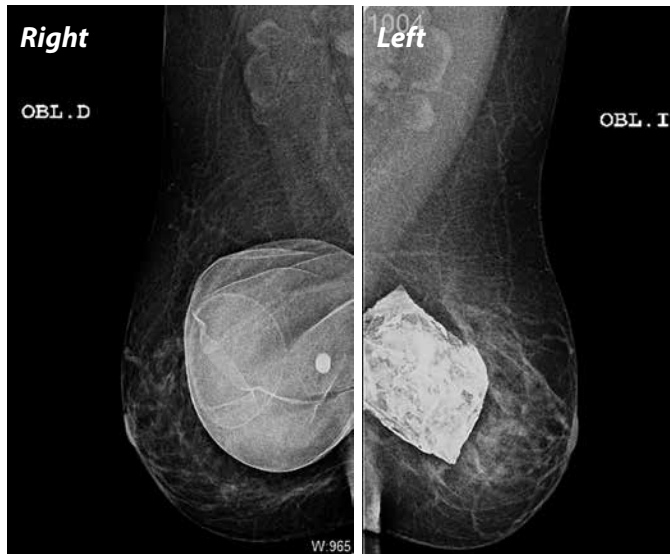


Figure 4. a). Comparative MLO mammography. Right: Normal aspect of a NSS prosthesis. Left: NSS implant with rupture signs and partial collapse.

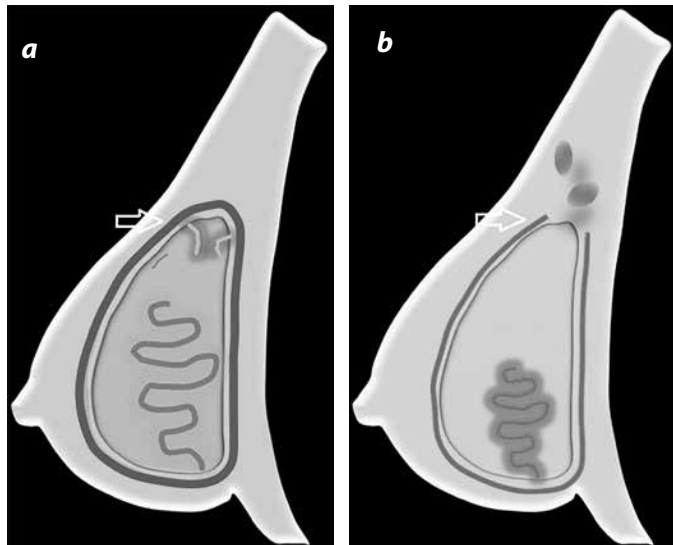


Figure 5. Classification of silicone breast implant ruptures. a) Intracapsular: Rupture of the cover of the implant, with limited silicone due to the fibrous capsule (arrow). b) Extracapsular: rupture of the implant and of the fibrous capsule (arrow), with macroscopic silicone in breast tissue and adjacent ganglia.

Besides, there is the filtration of silicone that consists in microscopic leaks of the implant's content through an intact cover (3,13). The migration of silicone to the ganglia can occur with two types of ruptures and with filtration of silicone (11).

The mammography has low sensitivity for detection of implant ruptures, 25-67% (24,30,31), its usefulness if the evaluation of the adjacent mammary tissue. Intracapsular ruptures, which are the great majority, 77-89% (29), are not observed by mammography, reason for which, any change in the configuration of the implant is suggestive of rupture (3,13).

In MR and US there have been multiple intracapsular rupture signs described, which are comparable: "Sign of Linguini" in MR; "stair" in US; "lock" in MR; "echogenic folding" and sign of the "sub-capsular line", in MR (figures 6 and 7) (3,11-14,32-35).

The extracapsular rupture can be diagnosed by mammography, in US or MR. In mammography dense silicone can be observed in the interior of the mammary parenchyma or in the ganglia (figure 8a). In ultrasound, the most characteristic is the sign of the "snow storm" in the mammary tissue or in lymphatic ganglia (3), also silicone agglomerations can be seen in the form of cysts (figure 8b and 8c) (32).

The MR is the best method to determine the extension of free silicone in the mammary tissue. It is visualized best in the T2-selective sequences (figure 8d). When silicone granulomas are formed the signal intensity is high intermediate in the T2 (25).

In CAT the findings are incidental, the extracapsular rupture is not obvious due to similar density of silicone and soft tissues (3). In the intracapsular ruptures one can observe similar signs to those in MR (figure 9).

Although breast MR is the most sensitive and specific study for rupture diagnose, it is expensive and not easily accessible in our medium, for which, the actual recommendation to evaluate implant integrity is the ultrasound as a study approach given its sensitivity, 50 - 77% and high VPN > 90% (13, 34, 35). This last means that a negative ultrasound firmly supports the integrity of the implant, and leaves the MR only for difficult cases - if clinical doubt persists-, in coherence with the cost-benefit studies (figure 10) (36-39).

### Late seroma

Is defined as a symptomatic intracapsular collection that develops after a year of surgery (40) and the main symptom is the increase of mammary tissue. It is an extremely rare complication, with publication in specialized literature indicating an incidence below 2% (41, 42).

Although the aetiology of this event is not clear, the possible causes are ruptures related to particular types of implants (more frequently with texturized ones), some degree of trauma, or subclinical infection (41, 43). Other reported cause is the giant cell anaplastic lymphoma.

The recommended conduct is the percutaneous drainage guided by ultrasound to study the liquid, with the aim to discard infection or malignancy (figure 11) (41-43).

## Systemic complications

### Tumour pathology, giant cell anaplastic lymphoma

The giant cell anaplastic lymphoma (GCAL) associated to implants is a relatively new and rare entity, with nearly 60 cases reported worldwide (44).

The pathogenesis is not fully understood and it is postulated that GCAL is originated in a local reactive process, incited by the implant and the secondary chronic inflammatory process (45-47).

The latency time since implant placement up to manifestation of the disease is variable, from a year up to 32 years after, with an average of 10.5 years (45,46). The GCAL courses, generally, without pain and confined to the fibrous capsule without invading the mammary parenchyma -it is not breast cancer-. In many cases it has been enough to retrieve the implant and to make a capsulectomy; notwithstanding, there have also been fatal cases described when it appears as a solid mass (47).

The MR findings described in the literature are similar to those of a late seroma. Additionally there can be or not enhancement of the capsule or associated solid mass (46,47).



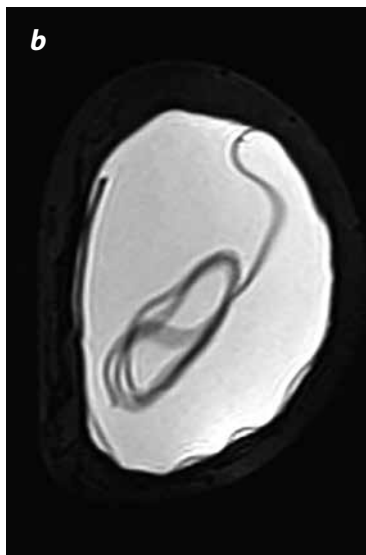
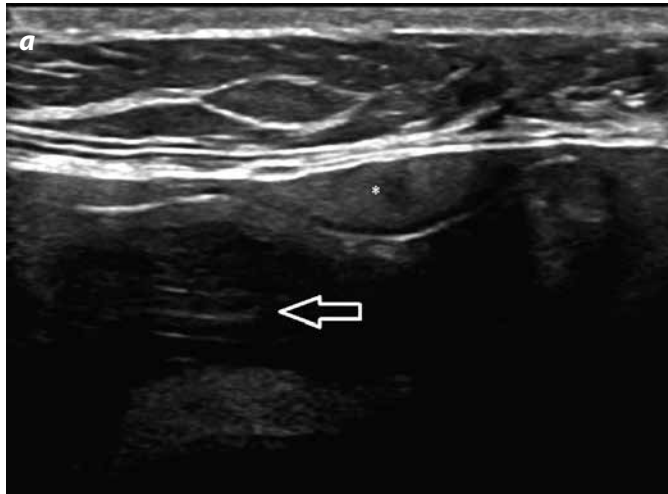


Figure 6. Intracapsular rupture. a) Ultrasound: sign of the "stair" (arrow): multiple discontinuous lines that represent the collapsed foldings of the implant. The sign of the "echogenic folding" (\*): silicone between the foldings. b) Breast MR T2-STIR coronal image with water saturation, the sign of "Linguini".

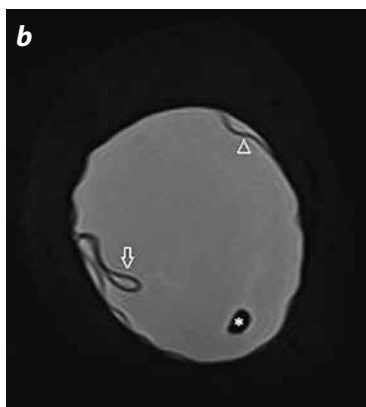
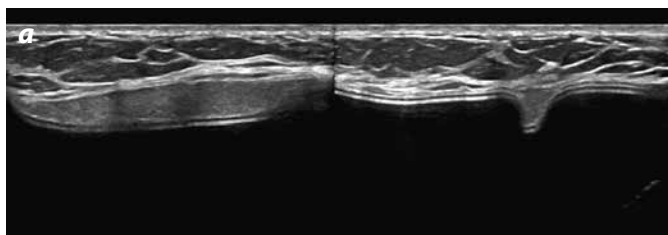


Figure 7. Intracapsular rupture. a) Breast ultrasound, sign of the "echogenic folding" in longitudinal and transversal planes. b) Breast MR, T2-STIR coronal image with water saturation: sign of the "lock" (arrow); sign of the "subcapsular line" (head of arrow) and water drop at the interior of the prosthesis (\*).

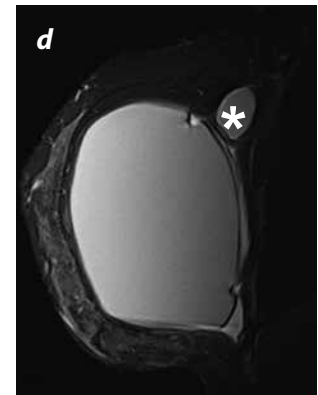
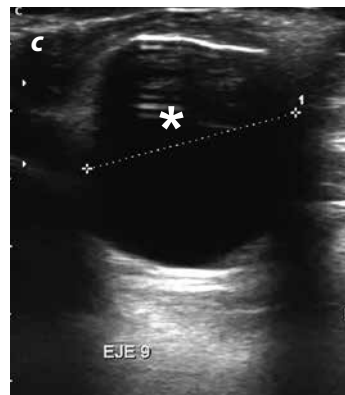
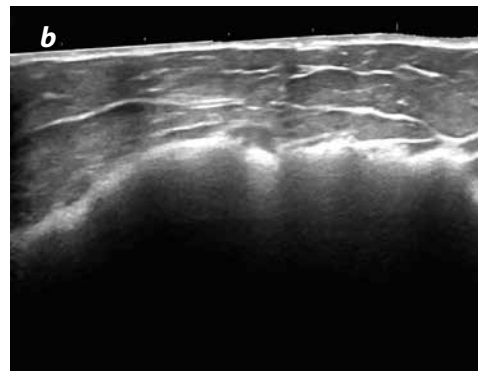
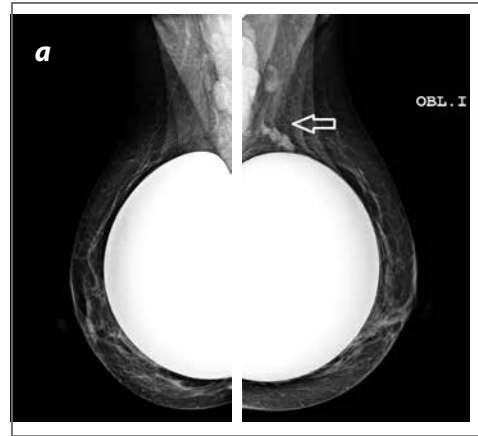


Figure 8. Extracapsular rupture. a) MLO mammography that shows free silicone (arrow) in the left mammary parenchyma and in ganglia. b) Echographic sign "snow storm". c) Cystic image (\*) that corresponds to the agglomeration of silicone in the mammary parenchyma. d) Breast MR, T2-STIR sagittal image, shows isointense extracapsular silicone (\*).

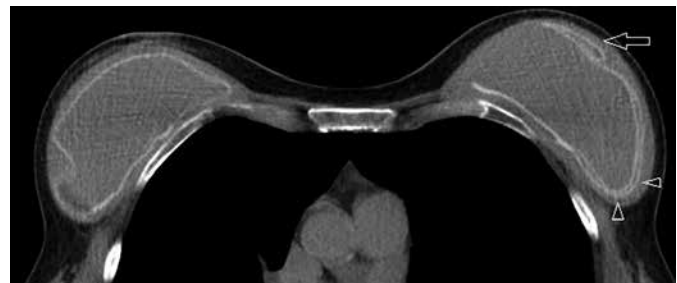

Figure 9. Axial thorax CT section. Sig of the "lock" (arrow), sign of the "subcapsular line" (arrow heads).

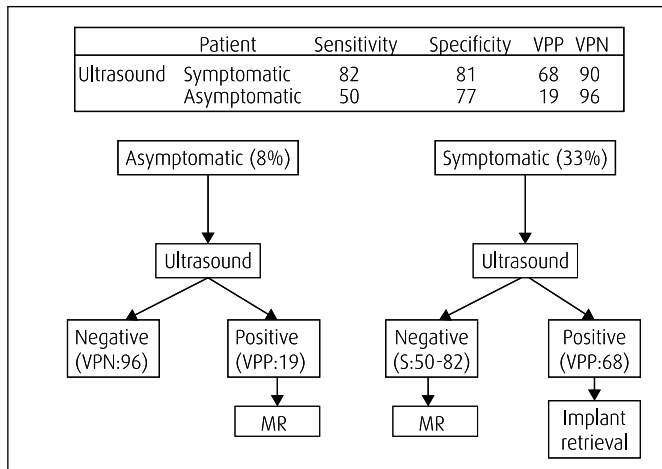


Figure 10. Diagnostic performance of ultrasound for detection of prosthesis rupture (superior box). Diagnostic algorithm of prosthesis rupture in asymptomatic and symptomatic patients.

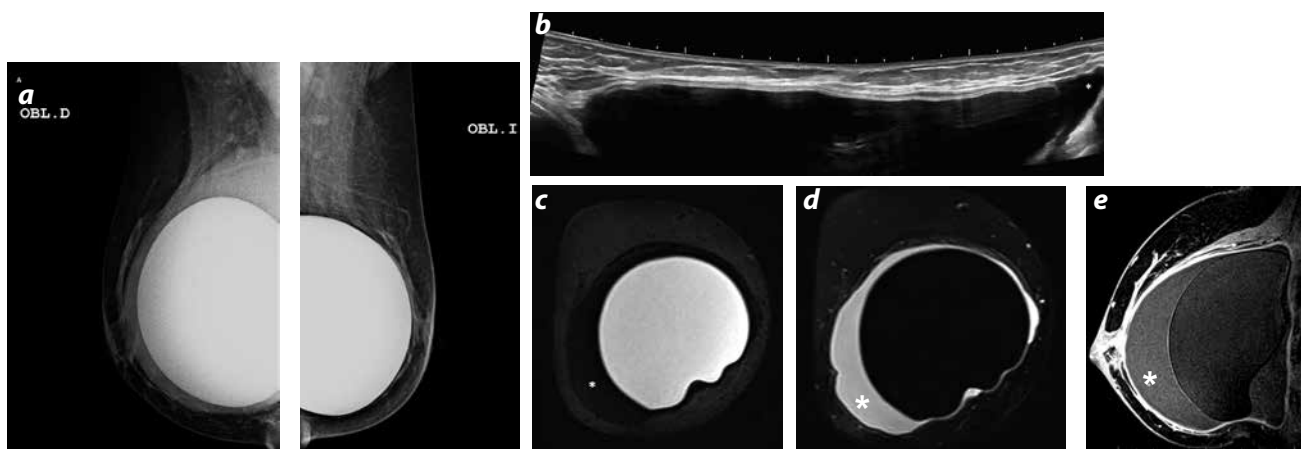


Figure 11. Late seroma. Silicone implant antecedent 7 years ago. a) Retropectoral implants with increase of peri-prosthetic density in the right side. b) Extended field ultrasound: intact breast implant with peri-prosthetic liquid (\*). c and d) MR right breast: coronal images, STIR sequences, water suppression and silicone suppression; intact implant, surrounded of intracapsular liquid (\*). e) MR right breast: sagittal image T1-3D FS with contrast medium: right peri-prosthetic liquid with discretely high signal (\*). Aspirated liquid report: reactive cellularity without atypical cytology. Negative cultures for bacteria, fungi and microbacteria.

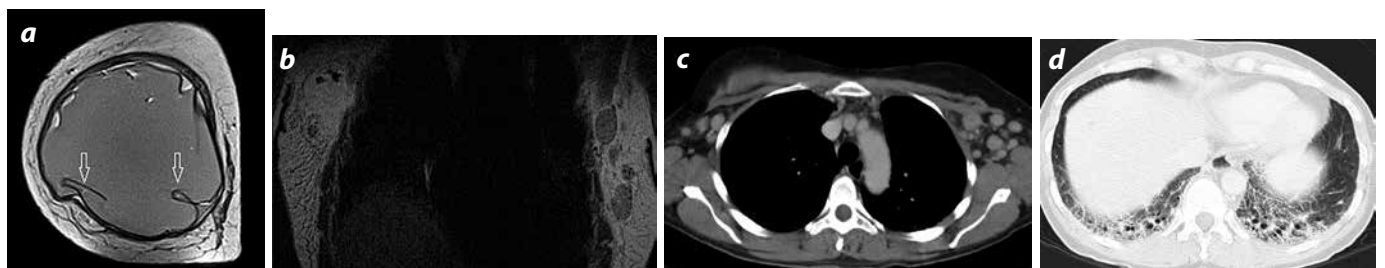


Figure 12. ASIA, breast implant antecedent 5 years ago. One month of evolution of unspecific symptoms, arthralgias and myalgias. Negative immunologic markers for a known rheumatic condition. a and b) MR coronal images with T2 information and sagittal with T1 information, with contrast medium: signs of intracapsular rupture (arrows), axillary lymphadenopathies. c and d) Thorax CAT: bilateral axillary lymphadenopathies and interstitial changes of the pulmonary bases. The biopsy of the striated muscle and of axillary ganglia showed myositis and lymphadenitis due to silicone. This patient gathered two of the major criteria proposed by Schoenfield and collaborators for the diagnosis of ASIA.

### Autoimmune / inflammatory syndrome induced by adjuvants (ASIA)

Silicone is considered an “adjuvant” substance, which has the capacity of inducing, in an indirect way, an immune antigen-antibody response in individuals that have certain immunological susceptibility. The immune response to the silicone receives the name of ASIA and manifests with symptoms such as fever, myalgias, arthralgias, arthritis, fatigue, cognitive disorders and depression. The physical

examination can present adenopathies. There are specific immunological tests for its diagnosis (48).

In ASIA the activated immune system cells, histocytes and macrophages have the capacity of breaking the cover of the implant, phagocyte and transport the silicone to the lymphatic ganglia where it is presented as an antigen, to, finally, trigger the immune response. In images, rupture of the prosthesis can be observed, and can be associated to fibrotic changes in the lung parenchyma (figure 12) (49,50).

## Conclusion

Nowadays, low frequency complications associated to breast implant have taken more importance, being more evident (relative frequency) given the significant increase of breast augmentation surgery. Because of this it is of vital importance for the radiologist the recognition of infrequent complications derived from breast implants.

In our institution the consults related to complications stemming from breast implants and, likewise, the request for ultrasounds for its detection are more frequent. Knowing to recognize the described signs and the physiopathology of low frequency complications is an indispensable requisite to improve this diagnostic exercise.

## References

- International Society of Aesthetic Plastic Surgery (ISAPS). ISAPS International Survey on Aesthetic/Cosmetic Procedures Performed in 2014 [internet]. 2014 [citado 2015 ago. 15]. Disponible en: [http://www.isaps.org/Media/Default/global-statistics/2015%20%20ISAPS Results.pdf](http://www.isaps.org/Media/Default/global-statistics/2015%20%20ISAPS%20Results.pdf)
- Juanpere S, Perez E, Huc O. Imaging of breast implants—a pictorial review. *Insights Imaging*. 2011;2:653-70.
- Herborn C, Borut M, Daniel E, et al. Breast augmentation and reconstructive surgery: MR imaging of implant rupture and malignancy. *Eur Radiol*. 2002;12:2198-206.
- Hölmich Lisbet R, Fryzek Jon P, Kim K, et al. The diagnosis of silicone breast-implant rupture clinical findings compared with findings at magnetic resonance imaging. *Ann Plast Surg*. 2005;54:583-9.
- Gorzycza D, Gorzycza S, Gorzycza K. The diagnosis of silicone breast implant rupture. *Plast Reconstr Surg*. 2007;120(Suppl1):49S-61S.
- Gampper T, Khoury H. Silicone gel implants in breast augmentation and reconstruction. *Ann Plastic Surg*. 2007;59: 581-90.
- Neal H. The effect of silicone implants on the diagnosis, prognosis, and treatment of breast cancer. *Plast Reconstr Surg*. 2007;120(Suppl. 1):81S.
- Miglioretti D, Rutter C, Geller B, et al. Effect of breast augmentation on the accuracy of mammography and cancer characteristics. *JAMA*. 2004;291:442-50.
- Silverstein MJ, Handel N, Gamagami P, et al. Breast cancer in women after augmentation mammoplasty. *Arch Surg*. 1988;123:681.
- Eklund GW, Busby RC, Miller SH, et al. Improved imaging of the augmented breast. *AJR*. 1988;151:469.
- Lake E, Ahmad S, Dobrashian R. The sonographic appearances of breast implant rupture. *Clin Radiol*. 2013;68:851-8.
- Brenner J. Evaluation of breast silicone implants. *Magn Reson Imaging Clin N Am*. 2013;21:547-60.
- Yang N. The augmented breast: A pictorial review of the abnormal and unusual. *AJR*. 2011;196:451-60.
- Venkataraman S, Hines N. Challenges in mammography: Part 2, Multimodality review of breast augmentation. Imaging findings and complications. *AJR*. 2011;197:W1031-45.
- O'Toole M, Caskey CI. Imaging spectrum of breast implant complications: mammography, ultrasound, and magnetic resonance imaging. *Semin Ultrasound CT MR*. 2000;21:351-61.
- Washer L, Gutowski K. Breast implants infections. *Infect Dis Clin N Am*. 2012;26:111-25.
- Hvilsom G, Holmich L, Henriksen T, et al. Local complications after cosmetic breast augmentation: results from the Danish Registry for Plastic Surgery of the Breast. *Plast Surg Nurs*. 2010;30:172-9.
- Harris KM, Ganott MA, Shestak KC, et al. Silicone implant rupture: detection with US. *Radiology*. 1993;187:761-8.
- Vistnes LM, Ksander GA. Tissue response to soft tissue silicone prostheses: capsule formation and other sequelae. En: Rubin LR, editor. *Biomaterials in reconstructive surgery*. St Louis (MO): Mosby; 1983. p. 516-28.
- Gabriel SE, Woods JE, O'Fallon WM, et al. Complications leading to surgery after breast implantation. *N Engl J Med*. 1997;336:677-82.
- Handel N, Jensen JA, Black Q, et al. The fate of breast implants: a critical analysis of complications and outcomes. *Plast Reconstr Surg*. 1995;96:1521-33.
- Burkhardt BR. Capsular contracture: hard breast, soft data. *Clin Plast Surg*. 1988;15:521-32.
- Ganott MA, Harris KM, Ilkhanipour ZS, et al. Augmentation mammoplasty: normal and abnormal findings with mammography and US. *RadioGraphics*. 1992;12:281-95.
- Glynn C, Litherland J. Imaging breast augmentation and reconstruction. *Br J Radiol*. 2008;81:587-95.
- Middleton MS. MR evaluation of breast implants. *Radiol Clin N Am*. 2014;52:591-608.
- Spear SL, Parikh PM, Goldstein JA. History of breast implants and the Food and Drug Administration. *Clin Plast Surg*. 2009;36:15-21.
- Maijers MC, Niessen FB, Veldhuizen JFH. MRI screening for silicone breast implant rupture: accuracy, inter- and intraobserver variability using explantation results as reference standard. *Eur Radiol*. 2014;24:1167-75.
- US Food and Drug Administration data [internet]. 2013 [citado 2015 ago. 15]. Disponible en: <http://www.fda.gov/medicaldevices/productsandmedicalprocedures/implantsandprosthetics/breastimplants>.
- Brown SL, Middleton MS, Berg WA, et al. Prevalence of rupture of silicone gel breast implants revealed on MR imaging in a population of women in Birmingham, Alabama. *AJR*. 2000;175:1057-64.
- Colombo G, Ruvolo V, Stifanese R, et al. Prosthetic breast implant rupture: imaging pictorial essay. *Aesth Plast Surg*. 2011;Apr 13
- Destouet JM, Monsees BS, Oser RF, et al. Screening mammography in 350 women with breast implants: prevalence and findings of implant complications. *Am J Roentgenol*. 1992;159:973-8
- Berg WA, Nguyen TK, Middleton MS, et al. MR imaging of extra-capsular silicone from breast implants: diagnostic pitfalls. *AJR Am J Roentgenol*. 2002;178:465-72.
- Rosculiet KA, Ikeda DM, Forrest ME, et al. Ruptured gel-filled silicone breast implants: sonographic findings in 19 cases. *AJR Am J Roentgenol*. 1992;159:711-6.
- Venta LA, Salomon CG, Flisak ME, et al. Sonographic signs of breast implant rupture. *AJR*. 1996;166:1413-9.
- Caskey CI, Berg WA, Anderson ND, et al. Breast implant rupture: diagnosis with US. *Radiology*. 1994;190:819-23
- Hold PM, Alam S, Pilbrow WJ, et al. How Should We Investigate Breast Implant Rupture? *Breast J*. 2012;18:253-6.
- Chung KC, Malay S, Shauver MJ, et al. Economic analysis of screening strategies for rupture of silicone gel breast implants. *Plast Reconstr Surg*. 2012;130:225-37.
- Stoblen F, Rezaei M, Kummel S. Imaging in patients with breast implants results of the First International Breast (Implant) Conference 2009. *Insights Imaging*. 2010;1:93-7.
- Royal College of Radiologists. Board of the faculty of Clinical Radiology, Guidance on Screening and Symptomatic Breast Imaging (2nd ed.) [internet]. 2003 [citado 2015 ago. 15]. Disponible en: <http://www.rcr.ac.uk/publications.aspx>
- Spear S, Rottman S, Glicksman C, et al. Late seromas after breast implants: Theory and practice. *Plast Reconstr Surg*. 2012;130:439-40.
- Pinchuk V, Tymofii O. Seroma as a late complication after breast augmentation. *Aesthetic Plast Surg*. 2011;35:303-14.
- Mazzocchi M, Dessy L, Corrias F. A clinical study of late seroma in breast implantation surgery. *Aesth Plast Surg*. 2012;36:97-104.
- Oliveira VM, Roveda Junior D, Lucas FB, et al. Late seroma after breast augmentation with silicone prostheses: A case report. *Breast J*. 2007;13:421-3.
- US Food and Drug Administration (FDA). FDA medical device communication: reports of anaplastic large cell lymphoma (ALCL) in women with breast implants [internet]. 2011 [citado 2015 ago. 15]. Disponible en: <http://www.fda.gov/medicaldevices/safety/alertsandnotices/ucm240000.htm>
- Story S, Schowalter M. Breast implant associated ALCL: A unique entity in the spectrum of CD30+lymphoproliferative disorders. *The Oncologist*. 2013;18:301-7.
- George E, Pharm J, Houston C. Breast implant-associated ALK-negative anaplastic large cell lymphoma: a case report and discussion of possible pathogenesis. *Int J Clin Exp Pathol*. 2013;6:1631-42.
- Aladily T, Medeiros J, Amin M. Anaplastic large cell lymphoma associated with breast implants: A report of 13 cases. *Am J Surg Pathol*. 2012;36:1000-8.
- Shoenfeld Y, Agmon-Levin N. "ASIA" autoimmune/inflammatory syndrome induced by adjuvants. *J Autoimmun*. 2011;36:4-8.
- Miyata Y, Okano R, Kuratomi Y. Interstitial pneumonia associated with human adjuvant disease which developed 30 years after silicone augmentation mammoplasty. *Nihon Kyobu Shikkan Gakkai Zasshi*. 1997;35:1093-8.
- Pineda J, Díaz J, Agualimpia A. Autoimmune/inflammatory syndrome induced by adjuvants causing myositis and pulmonary fibrosis. *IMAJ*. 2013;15:720-72.

## Corresponding Author

Oscar Eduardo García Ledesma  
 Departamento de Radiología  
 Fundación Clínica Valle del Lili  
 Av. Simón Bolívar Carrera 98 # 18-49  
 Cali, Colombia  
[oscaredumd@hotmail.com](mailto:oscaredumd@hotmail.com)

Received for evaluation: August 24, 2015  
 Accepted for publication: March 11, 2016